



PATIENT

Murphy Philbert

SPECIES

Canine

BREED

Golden Mix

SEX

MN

AGE

6

WEIGHT

94

INTERPRETED BY

R. McKenzie Daniel,
DVM, DABVP
(Canine and Feline)

IMAGING PERFORMED BY

Jenn

HOSPITAL NAME

Rockaway Animal
Hospital

REFERRING VET

Dr Maniar

INVOICE

24874

DATE

05/19/2026

PRESENTING CLINICAL SIGNS

Hx of Addison's vomiting eating

Abnormal PE/Chem/CBC/UA Results: Lipase 548

ULTRASONOGRAPHIC EXAMINATION OF THE ABDOMEN

Urinary System

The urinary bladder, trigone, cystourethral junction, and visible pelvic urethra to a depth of 2 cm exhibited normal thickness and tone. Anechoic urine was present in the lumen with no evidence of urine/lumen sediment, mineral, or calculi. The ureteral papillae were normal. The ureters were not visible which is normal. No evidence of inflammatory or neoplastic changes was noted.

Normal size and margination were present in the kidneys. A normal 1:3 cortex / medulla ratio and normal corticomedullary definition were maintained. The echogenicity of the cortex was similar to or slightly less than normal liver parenchyma while the medulla echogenicity was hypoechoic to the cortex with no evidence of pelvic dilation. The left kidney measured 7.4 cm in length. The right kidney measured 7.1 cm in length.

The area of the aortic trifurcation was free of pathology.

Adrenal Glands

The left adrenal gland was small in size with flattened contour and a uniformly hypoechoic parenchyma. The left adrenal gland measured 0.38 cm width at the caudal pole. The right adrenal gland was not definitively visualized owing to subnormal size and consistent with patient history.

Spleen

The spleen exhibited a finely textured and homogenous parenchyma which was hyperechoic to the liver and renal cortical parenchyma. The capsule was smooth and regular without apparent expansion. The splenic vasculature at the hilus was normal in volume with no evidence of congestion or thrombosis. Acute to chronic inflammatory, neoplastic, or benign parenchyma changes were not noted.

Liver/Gallbladder

The liver was subjectively normal in size, structure, and contour. The liver parenchyma was uniform and hypoechoic to the spleen with a mild coarse echotexture. Normal vascular volume. The hepatic and portal vasculature were normal in appearance without signs of congestion. The gallbladder was non-distended in size with thin walls and primarily anechoic luminal content. The cystic and common bile ducts were normal.

Gastrointestinal

The stomach presented intact wall layering with a normal wall layer ratio. The lumen of the stomach contained mild hyperechoic non-shadowing to progressively shadowing ingesta with no signs of obstruction or foreign material.

The small intestine presented intact wall layering with 1:3 muscularis/mucosa ratio. The lumen of the small intestine was empty with no signs of mechanical/metabolic ileus, obstruction or foreign material.



PATIENT

Murphy Philbert

SPECIES

Canine

BREED

Golden Mix

SEX

MN

AGE

6

WEIGHT

94

INTERPRETED BY

R. McKenzie Daniel,
DVM, DABVP
(Canine and Feline)

IMAGING PERFORMED BY

Jenn

HOSPITAL NAME

Rockaway Animal
Hospital

REFERRING VET

Dr Maniar

INVOICE

24874

DATE

05/19/2026

Normal visible colon wall layers were present with apparent formed feces in lumen.

Pancreas

The area of the pancreas was sonographically normal.

Free Abdomen

No omental masses, overt lymphadenopathy or peritoneal effusion was present.

ULTRASONOGRAPHIC FINDINGS

Primary

- Sonographically unremarkable gastrointestinal tract with gastric ingesta
- Normal area of pancreas
- Bilateral subnormal adrenal glands-consistent with patient history

INTERPRETATION OF THE FINDINGS & FURTHER RECOMMENDATIONS

Recheck adrenal testing may be considered if not recently done. Mild pancreatitis may present sonographically normal and may be suspected if cranial abdomen/subxiphoid discomfort on palpation. The presence of gastric ingesta is nonspecific and may indicate post-prandial presentation. Correlation with most recent meal ingestion is recommended.

If clinically indicated, documented 12-hour fast and sonographic monitoring of gastric emptying with supportive care, which may include dietary trial and as needed gastric protectants is recommended.



PATIENT

Murphy Philbert

SPECIES

Canine

BREED

Golden Mix

SEX

MN

AGE

6

WEIGHT

94

INTERPRETED BY

R. McKenzie Daniel,
DVM, DABVP
(Canine and Feline)

IMAGING PERFORMED BY

Jenn

HOSPITAL NAME

Rockaway Animal
Hospital

REFERRING VET

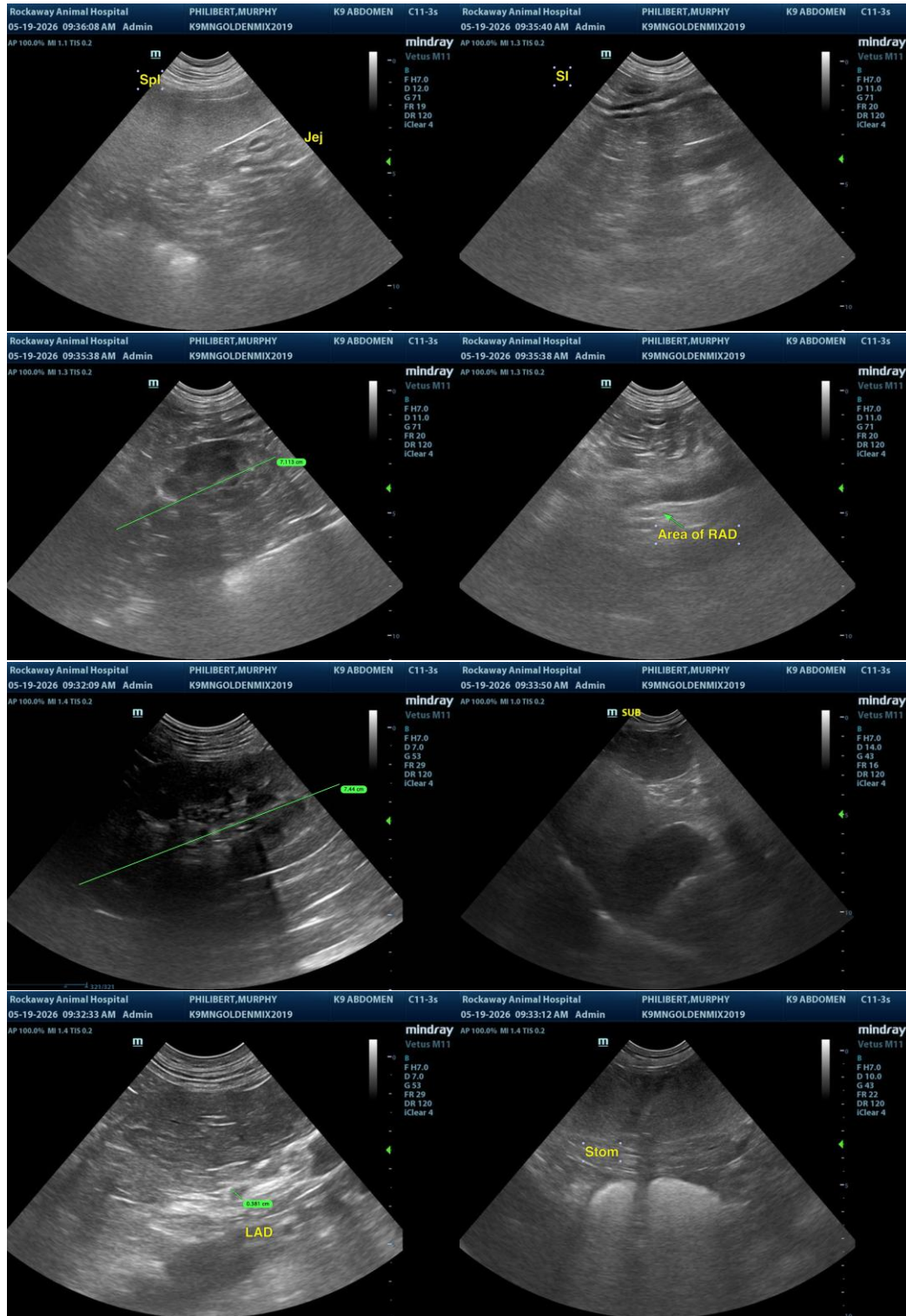
Dr Maniar

INVOICE

24874

DATE

05/19/2026



The information and recommendations provided are based on the images presented by the referring veterinarian/sonographer. No evaluation can be communicated regarding pathology that was not



PATIENT

Murphy Philbert

visible in the image/video clips provided.

Thank you for this referral. If the clinical or image interpretation does not parallel your findings or if I can be of any further assistance, please contact me.

SPECIES

Canine

R. McKenzie Daniel, DVM, DABVP (Canine/Feline Practice)

info@sonopath.com

BREED

Golden Mix

SEX

MN

AGE

6

WEIGHT

94

INTERPRETED BY

R. McKenzie Daniel,
DVM, DABVP
(Canine and Feline)

IMAGING PERFORMED BY

Jenn

HOSPITAL NAME

Rockaway Animal
Hospital

REFERRING VET

Dr Maniar

INVOICE

24874

DATE

05/19/2026